

Table of Contents

Preface *vii*

1

Basic Surgical Principles 1

2

Indications for Each Implant Type 17

3

Surgical Procedures in Standard Nonesthetic Sites 23

4

Surgical Procedures in Standard Esthetic Sites 39

5

Surgical Procedures for Implant Placement with Simultaneous Guided Bone Regeneration 61

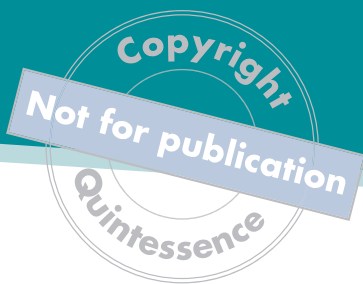6

Surgical Procedures for Implant Placement with Simultaneous Sinus Floor Elevation 77

7

Clinical Cases 93

Suggested Reading 123



Preface

Based on the concept of osseointegration first described by Brånemark and Schroeder, implant dentistry has evolved tremendously over the past 15 years, and today it plays an integral role in dental rehabilitation. Though it was developed primarily to rehabilitate fully edentulous patients, since the late 1980s the treatment focus has gradually shifted to partially edentulous patients. Today, single-tooth replacement is the number one indication for implant therapy.

Implant dentistry also has benefited from the significant progress made in associated treatment protocols. Development of bone augmentation procedures allows clinicians to correct alveolar bone deficiencies, while guided bone regeneration with barrier membranes and sinus floor elevation have become standards of care to correct bone defects in other parts of the oral cavity. In addition, improved osteophilic microtextured titanium implant surfaces help to accelerate healing, significantly reducing treatment time. Together, these advances make implant therapy more predictable and more attractive to patients, and the result has been a rapid expansion of implant dentistry in daily practice and more clinicians placing dental implants.

This book is the culmination of many years' effort to standardize surgical technique in implant dentistry. It is designed for postdoctoral students and practitioners who wish to perform surgical implant procedures in daily practice with a high predictability for success and a low risk for complications. Basic surgical principles and procedures for placing implants both in standard sites and in sites with local defects are presented using detailed explanations and hand-drawn illustrations. The final chapter of the book presents 14 comprehensive clinical case reports, several documenting long-term follow-ups over a period of 10 years.

The publication of this book coincides with the production of a DVD featuring live surgery of the same surgical techniques in seven clinical cases. The surgery was recorded during master courses in implant dentistry offered by the University of Bern.

The authors wish to thank the staff of Quintessence Publishing for their excellent support during the preparation and production of this book.

Copyright
Not for publication
Quintessence

Fig 3-4 Soft tissue suturing of a mandibular distal extension situation with one implant.

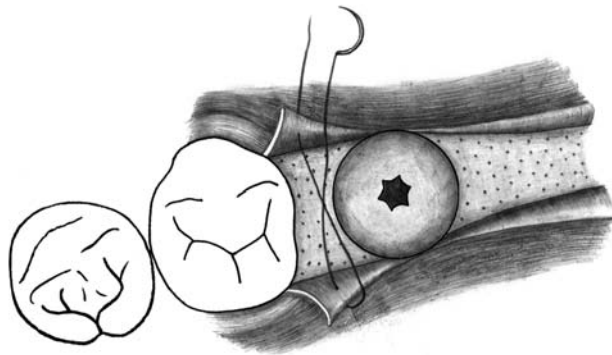


Fig 3-4a Occlusal view following placement of a wide neck implant in the mandibular first molar site. Closure of the flaps begins with the mesial papilla.

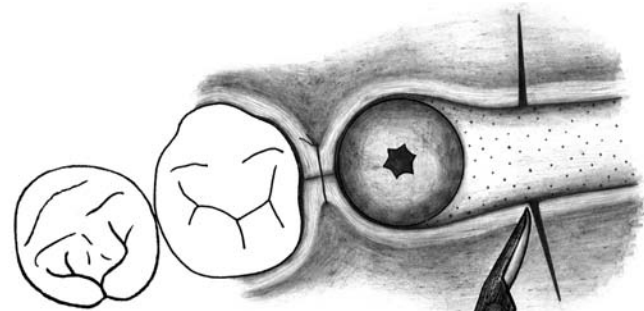


Fig 3-4b Once the mesial papilla is secured, relieving incisions are made approximately 3 mm distal to the implant to ensure a tension-free closure and obtain an adequate band of keratinized mucosa surrounding the implant.

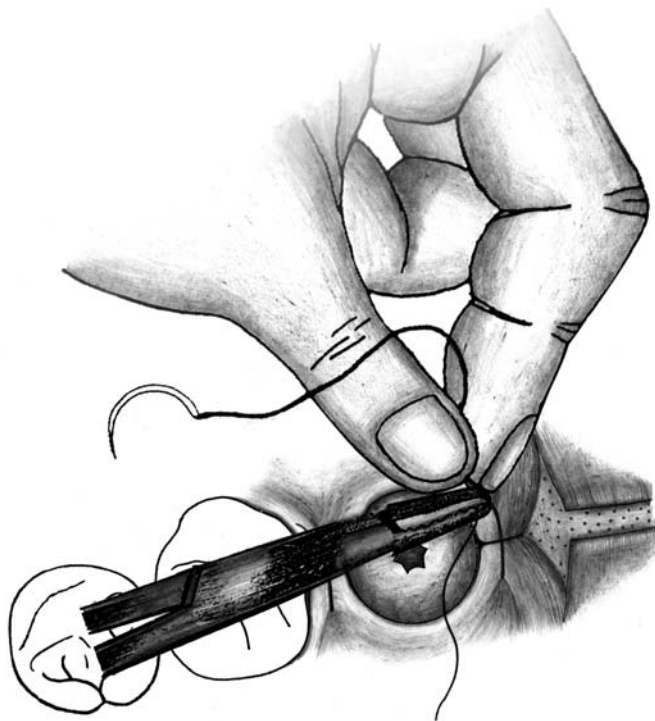


Fig 3-4c The buccal and lingual wound margins are rotated in slightly and sutured.

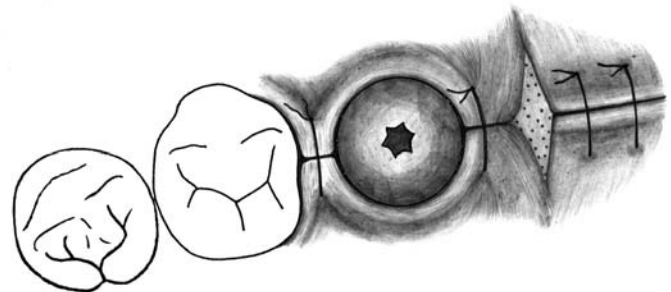


Fig 3-4d The remaining surgical site is closed with interrupted single sutures. The slight exposure of the bone distal to the implant site will heal by granulation.

Fig 6-10 Implant placement following sinus floor elevation.

Fig 6-10a A 10-mm wide neck implant is slowly inserted to the correct depth using a contra-angle handpiece at a speed of 15 rpm.

Fig 6-10b The insertion device is removed in a counterclockwise rotation.

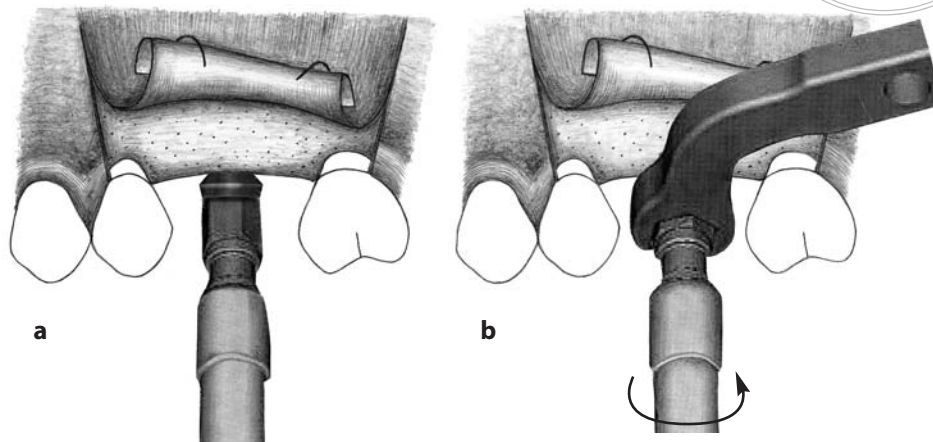


Fig 6-10c A 3-mm healing cap is attached to the implant to extend the implant above the soft tissue level and allow for a nonsubmerged healing.

Fig 6-10d To complete the surgery, the flap is repositioned and sutured crestally with two interrupted single sutures.

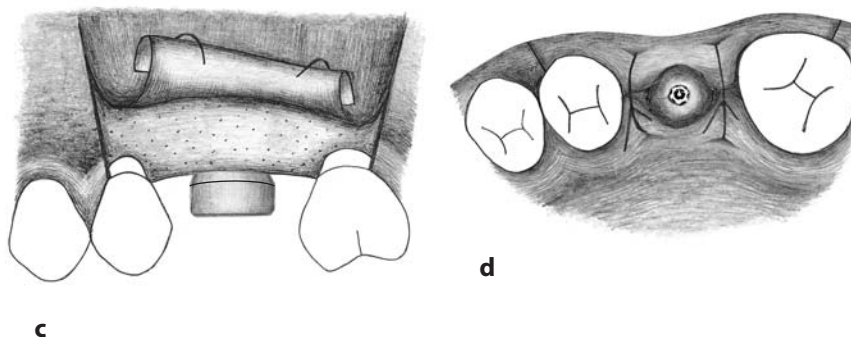
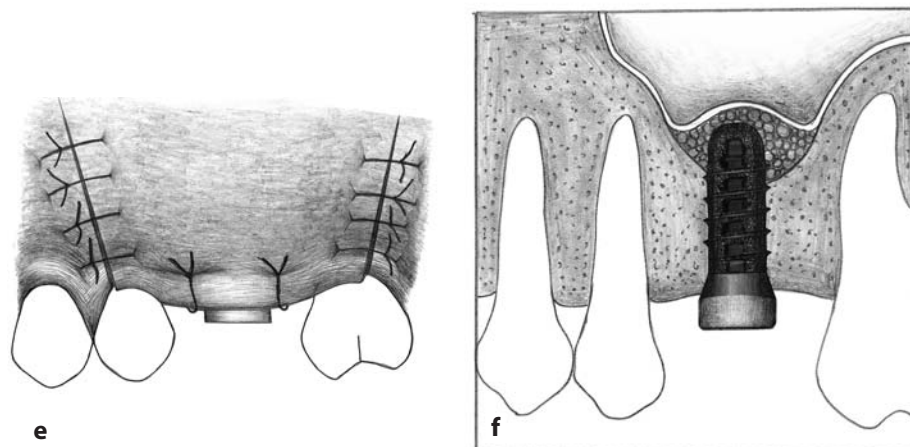


Fig 6-10e Finally, several interrupted single sutures close the releasing incisions.

Fig 6-10f Schematic cross section showing the 10-mm wide neck implant in place and the elevated sinus membrane following the application of bone augmentation material. The healing period will take 8 weeks before the implant can be restored with a single crown.



Copyright
Not for publication
Quintessence

Case 6 Standard implant placement, extended edentulous gap in the posterior maxilla.

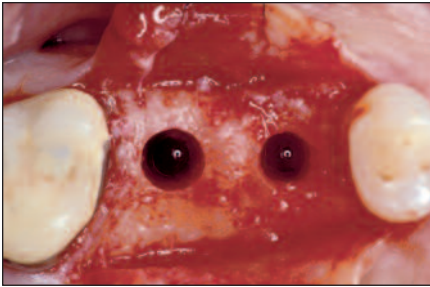


Fig 7-6a Two teeth are missing in the right posterior quadrant of the maxilla. Following a midcrestal incision and flap elevation, the implant site is prepared for appropriate prosthetic positioning.

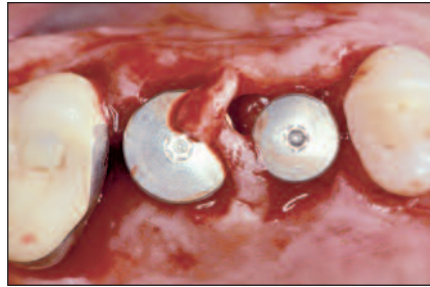


Fig 7-6b Following placement of two SLA-surfaced standard implants and 3-mm healing caps, the wound margins are adapted to the implant shoulders. In this case, small pedicle flaps are prepared to allow tension-free wound closure around the implants.

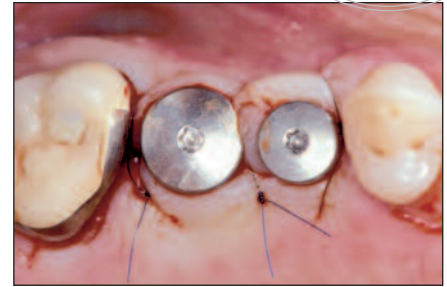


Fig 7-6c The wound margins are secured with three interrupted single sutures.

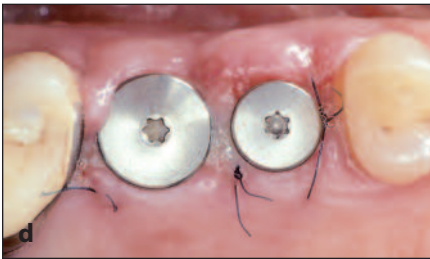


Fig 7-6d After 1 week, soft tissue healing has progressed and the sutures can be removed.

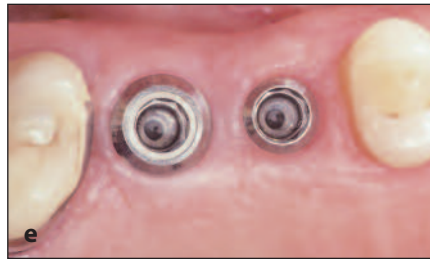

Fig 7-6e Six-week follow-up view showing excellent soft tissue healing. Both implants are well integrated and demonstrate favorable stability.

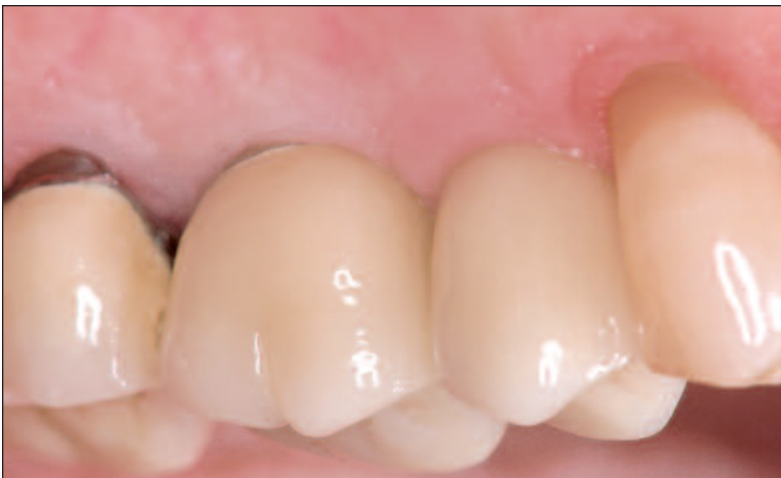

Fig 7-6f Clinical status at the 4-year follow-up. Both implants are restored with cemented ceramometal crowns without splinting.

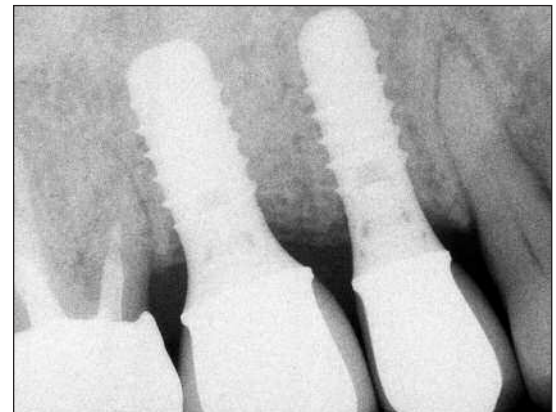


Fig 7-6g Four-year periapical radiograph showing well-integrated implants with stable alveolar bone levels.